

# OADDL E-News

## In this Issue

Impact of 2017 Wildfires on Oklahoma Livestock.....	1
Canine Flu.....	2
BVDV Ear Notch Testing in Cattle: ELISA vs. IHC.....	2
Is This Really a Parasite?.....	3
Recent Tularemia Case.....	3
Director's Note.....	4
Getting to Know Us.....	4
Request for Feedback.....	4

## Faculty

### Director:

Dr. Keith L. Bailey – Pathology

### Assistant Director/Quality Manager:

Emily J. Cooper

### Microbiology/Molecular Diagnostics:

Dr. Akhilesh Ramachandran

### Parasitology:

Dr. Yoko Nagamori

### Pathology:

Dr. Melanie A. Breshears

Dr. Anthony W. Confer

Dr. Grant Rezabek

Dr. Jerry Ritchey

Dr. Tim Snider

### Serology:

Dr. Grant Rezabek

### Graphic Design/Layout:

Clarissa Walton

## Impact of 2017 Wildfires on Oklahoma Livestock

In early March several wildfires burned large amounts of land in the Oklahoma Panhandle, Texas Panhandle, and Southwest Kansas. Approximately 310,000 acres in Northwest Oklahoma burned in four separate fires.

Approximately 3,000 cattle were killed or had to be euthanized because of the fires. One sow farm burned causing the loss of 6,000 sows and an unknown number of piglets.

Dr. Derrell Peel, Professor in the Department of Agricultural Economics at Oklahoma State University, estimates that losses in grass and feed, fencing, structures, and livestock total \$14.6 million to the cattle industry and a little over \$2 million for the hog facility.

Reports from my inspector in that part of the state are that grass is coming back well in all but the very sandy soil, which will take longer.

People in Oklahoma and all across

the country as always donated funds, hay, feed and fencing supplies to help those impacted get started rebuilding.

– Dr. Rod Hall, State Veterinarian



CENTER FOR VETERINARY HEALTH SCIENCES  
**Healthy Animals — Healthy People**



## Protect your horses from West Nile Virus (WNV)

In 2016, Oklahoma reported 16 clinical cases of neurologic disease in horses attributed to infection with WNV. The first case was reported on July 28.

Source: Equine Disease Communication Center

## BVDV Ear Notch Testing in Cattle: ELISA vs. IHC

The most common diagnostic tests used for the detection of bovine viral diarrhea virus (BVDV) in ear skin biopsies from cattle are antigen-capture ELISA (AgELISA) and immunohistochemistry (IHC). Both tests have high sensitivity for detecting cattle that are persistently infected (PI) with BVDV ([Cornish, 2005 JVDI](#)).

However, the AgELISA offers the following advantages when compared to IHC:



	ELISA	IHC
Results available	1 day	2-5 days
Skin can be frozen	Yes	No
Requires formalin	No	Yes
Skin sample can be used for confirmatory testing (e.g. PCR, virus isolation)	Yes	No
Degree of technical challenges at lab	Low	Moderate

## Canine Flu

Cases of influenza in dogs have recently been reported in Florida, Georgia, Kentucky, Louisiana, Missouri, North Carolina, South Carolina, Tennessee, Texas, Illinois and California. In 2016, infection with canine influenza was also diagnosed in sick cats in Wisconsin.

Despite these reports and the testing of client-owned and shelter dogs in Oklahoma, no cases of canine influenza have been diagnosed at OADDL as of July 7.

Clinical signs of canine influenza include coughing, lethargy,

oculonasal discharge, sneezing and fever. Pneumonia may be a secondary complication. Some dogs may also act as asymptomatic carriers and viral shedding can occur for several weeks post infection. Fortunately, the mortality rate is usually low.

OADDL offers a rapid polymerase chain reaction (PCR) test for canine influenza virus (CIV). The recommended specimen for testing includes two (2) nasal or pharyngeal swabs in a red-top tube.

– Dr. A. Ramachandran



Oklahoma Cattlemen's Association's 65th Annual Convention & Trade Show

**LOYAL** to the **COWBOY** for 65 Years

July 21 & 22, 2017 ~ Embassy Suites, Norman, Okla



## Is This Really a Parasite?

Diagnosing parasites in fecal flotations can be tricky. In order to correctly diagnose your patient, you must be able to differentiate true parasites from spurious parasites and pseudoparasites.

Spurious parasites are parasite eggs or oocysts from one host species

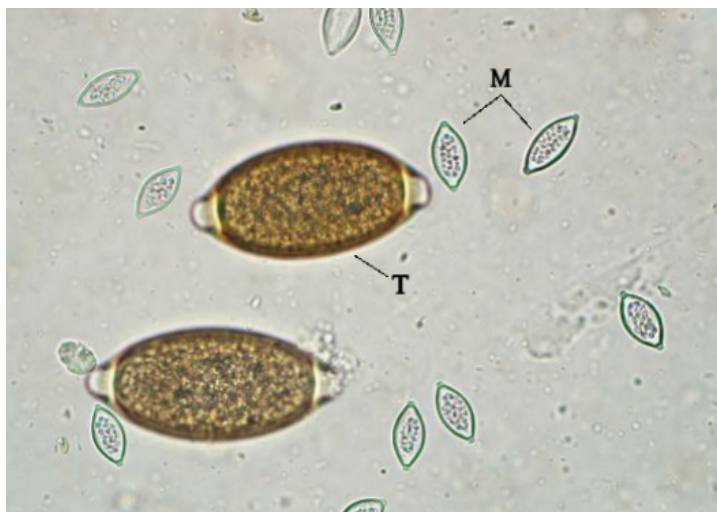that may be found in the feces of a scavenger or predator host. Common spurious parasites include *Monocystis* spp. (earthworm parasite; Fig 1) and *Eimeria* spp. in dogs and cats.

Pseudoparasites are ingested objects that resemble parasitic forms.

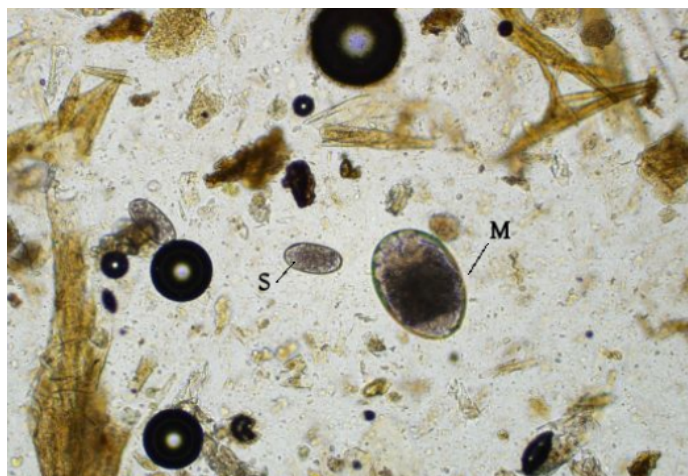
Common pseudoparasites include plant hairs, pollen, and grain mite eggs (Fig 2).

Animals do not need to be treated for spurious parasites or pseudoparasites.

– M. Wohltjen & Dr. Y. Nagamori



**Figure 1:** *Monocystis* sp. spores (M) have a similar shape as *Trichuris* sp. eggs (T), but are much smaller.



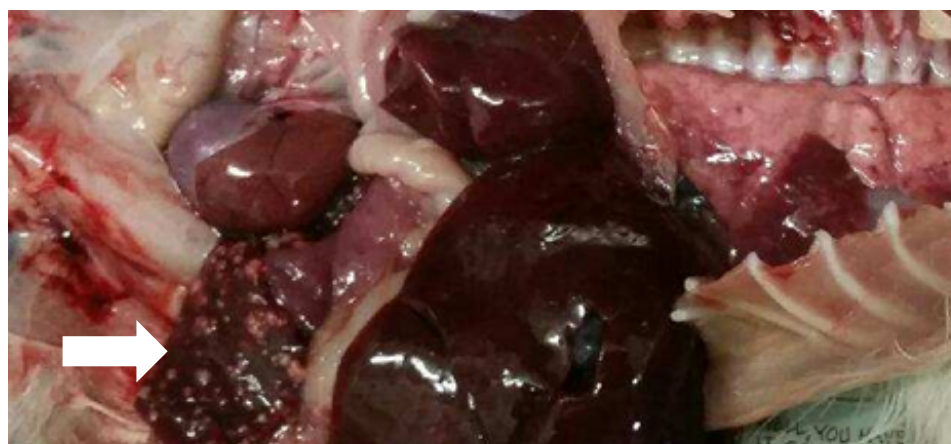**Figure 2:** Free-living mite eggs (M) are frequently found in ruminant feces and mistaken for *Nematodirus* sp. or fluke eggs because of their larger size when compared to strongylid eggs (S).

## Recent Tularemia Case: Unusual Clinical Features & Safer Diagnostic Testing

On June 23, tularemia was diagnosed in a 6-week-old kitten from northwest Oklahoma. At necropsy, the spleen was riddled with necrotic foci (Fig 1). Histologic lesions in the spleen, liver and lymph nodes were consistent with infection by *Francisella tularensis*, the causative agent of tularemia. The diagnosis was confirmed utilizing polymerase chain reaction (PCR) testing of formalin-fixed tissues.

The young age of the kitten in this case is unusual for tularemia, and also raises questions regarding transmission of disease. Usual transmission of *F. tularensis* to cats is either via ticks or associated with predation of infected rabbits or rodents. The dam of this kitten died immediately before the kitten died, but was not further investigated. The kitten was still actively nursing, raising the possibility of transmammary transmission as well.

*F. tularensis* is classified as a select agent and Category A bioterrorist pathogen, therefore confirmatory test-



**Figure 1:** Tularemia in a 6-week-old kitten. Note the prominent foci of necrosis in the spleen (arrow). Photo courtesy of Dr. Robert Cole.

ing poses safety risks to laboratory personnel. OADDL has developed a rapid PCR test utilizing formalin-fixed tissue to confirm infection. This new test eliminates the need to handle viable bacteria in fresh tissue (Fig 2).

– Drs. T. Snider & A. Ramachandran

**Figure 2:** Formalin-fixed spleen and liver for rapid PCR testing to confirm infection with *F. tularensis*.



## Letter from the Director

We are pleased to share this issue of our e-Newsletter with you. We began this e-Newsletter series in the summer of 2014 with the primary objectives of disseminating knowledge and exchanging new ideas. The format has been well received and our distribution continues to expand.

In this issue, the parasitology team enlightens us on spurious parasites and pseudoparasites. I must admit that prior to reading their draft article I had not given any thought to parasites of earthworms passing through the gastrointestinal tract of dogs and cats.

We have included a recent case of tularemia in a kitten as well as a new

and much safer way to confirm tularemia in specimens at OADDL. As with most things in life, there is always room for us to improve the way we approach things at the lab.

And lastly, we work daily to maintain our disease surveillance efforts by testing for diseases that have yet to be detected in Oklahoma (e.g. canine influenza) or have potential to devastate our livestock industries if they are introduced (e.g. avian influenza and foot-and-mouth disease).

The faculty and staff at OADDL wish you a safe and memorable summer!

— Dr. K. Bailey

**Think you've  
got sick cattle?  
It's time to play**

**DARTs!**

*DARTs is an acronym that helps producers to keep in mind likely tell-tale signs of poor animal health.*

*Just remember Depressed, Appetite, Respiration, and Temperature.*

*For more information, visit the DASNR website [here](#).*

## Getting to Know Us

Quinten Patterson is originally from San Antonio, Texas but was raised in Lubbock, Texas. He attended OSU, graduating in 2014, where he participated on the wrestling team and earned his BS in Biological Science. In his spare time, Quinten enjoys eating delicious food, playing video games, meeting new people, working out, hiking, cooking, reading, and spending time with his dog Haku.



Ryan Van Fleet is originally from Winfield, KS. He received his BS in Human Resource Management from Kansas State University in 1999. Ryan has been working at OADDL since the middle of April. In his free time he enjoys spending time with his family.




## Ideas/Suggestions for Future Content

We want to hear from you. Send us your ideas and suggestions to [oaddl@okstate.edu](mailto:oaddl@okstate.edu).

## Contact Us

Oklahoma Animal Disease  
Diagnostic Laboratory  
Ph: 405-744-6623  
Fax: 405-744-8612

[www.cvhs.okstate.edu/oaddl](http://www.cvhs.okstate.edu/oaddl)

 Follow us on Facebook

